

Bakers Cyst and its Analog on Elbow

Milovan Stojanović^{1,*}, Sonja Stojanović^{1,2}, Jovan Nedović¹, Slađana Božilov¹

¹Institute for Treatment and Rehabilitation-Niška Banja, Niška Banja, SERBIA.

²Faculty of Medicine, Niš University, Niš, SERBIA.

ABSTRACT

Bakers cyst is synovial cyst that is located in popliteal fossa. Rupture of meniscus and inflammatory diseases of synovial joints are the most common cause of Bakers cyst. Cyst diagnosis is based on a clinical picture, the ultrasound of knee and popliteal fossa and/or magnetic resonance imaging of the knee. The treatment includes bed rest, physical procedures, drugs, puncture and/or surgical removal of the cysts. All the above methods are effective in the treatment of cyst but not in the treatment of diseases that have led to the development of synovial effusion and the formation of cysts. Therefore, it is necessary to emphasize the importance of treating the primary disease that caused synovial cyst. Synovial cyst of knee joint is relatively common finding while cyst on elbow is a rare phenomenon.

Key words: Bakers cyst, Synovial cyst, Corticosteroids, Methotrexate, Elbow.

INTRODUCTION

Bakers cyst was named after the English surgeon William Marrant Baker who first described synovial cyst in popliteal fossa.¹ Rupture of meniscus and inflammatory diseases of the synovial joints such as rheumatoid, psoriatic or gouty arthritis are the most common causes of Bakers cyst.²⁻⁵ This conditions lead to overproduction of the synovial fluid which causes an increase in intra-articular pressure and leads to the formation of cysts in the popliteal pit.⁶

Cysts are usually asymptomatic and represent an accidental finding. When symptoms occur they are often non-specific and include pain or feeling of tension in the popliteal fossa, lack of full extension and flexion of the knee joint. Bakers cyst diagnosis is based on a clinical picture, the ultrasound scan and magnetic resonance imaging of the knee.^{7,8} Differential diagnosis is difficult especially towards thrombophlebitis.^{9,10}

The treatment includes bed rest, physical procedures, drugs, puncture and/or surgical removal of cysts.^{11,12} All the above methods are effective in the treatment of cyst but not in treatment of primary diseases which had

led to the development of synovial effusion. Therefore, it is necessary to emphasize the importance of treating the primary disease that caused overproduction of fluid.¹³

CASE 1

Patient R.V. born in 1946 was hospitalized on 09th of August 2018 at the Department of Rheumatology, Institute for Treatment and Rehabilitation Niska Banja because of pain and swelling in small joints of hands, wrists, shoulders and knee joints. This was his first hospitalization.

During physical examination swelling and tenderness of wrists and metacarpophalangeal joints was found. Also, tenderness of both elbows and shoulders as well as the existence of a large Bakers cyst in the right popliteal fossa (25-30cm x 5-6cm) and a small Bakers cyst in the left popliteal pit was noted (Figure 1).

Biochemical analyses indicated high sedimentation rate (54), an elevated level of leukocytes (10.4) and elevated level of rheumatoid factor (384). Radiography of

DOI: 10.5530/ijopp.12.3.41

Address for

correspondence:

Stojanovic Milovan,
Institute for Treatment and
Rehabilitation-Niska Banja,
Srpskih Junaka 2, Niska Banja,
Serbia.

Phone no: +38163771470

Email Id: milovanividosava@
gmail.com



www.ijopp.org

hands, feet and knee joints showed changes that were indicative for anatomical second stage of Rheumatoid Arthritis (RA).

The ultrasound examination of the knee joints registered moderate synovial effusion with marked synovial proliferation. In the left popliteal fossa, the existence of Bakers cyst with dimension 31mm x 5.3mm was noted. In the right popliteal pit, there was a large Bakers cyst filled with synovial proliferate. Dimension of right cyst was 30cm x 5cm (Figure 2 and 3).

During hospitalization patient was treated by parenteral administration of corticosteroids and analgesics with a good therapeutic effect. On the basis of clinical examination and performed diagnostic assays, it was concluded that patient suffered from seropositive RA with high clinical activity (DAS 28 6:59). We began basic therapy with methotrexate at a dose of 15mg per week and prednisone at a dose of 30 mg daily.

Three months after discharge from hospital patient came on scheduled control examination. Clinical examination revealed a regression of Bakers cyst in right popliteal pit (Figure 4 and 5).

On the basis of the clinical, laboratory analysis and ultrasonography of the joints it was determined that there was a rheumatoid arthritis remission and the dosage of corticosteroid was tapered to a dose of 5 mg per day.

CASE 2

The patient SR born in 1957. came on the 21st September 2018. At the scheduled hospital treatment at the Department of Rheumatology, Institute for Treatment and Rehabilitation Niska Banja because of morning stiffness which lasted about 30 min. Patients was diagnosed with seropositive RA back in 2016, after which she started basic therapy MTX at a dose of 10 mg per week. The dose of MTX was reduced to 7.5mg per

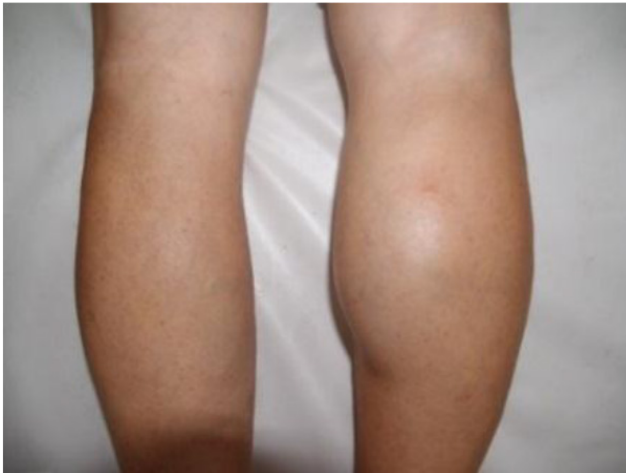


Figure 1: Bakers cyst.

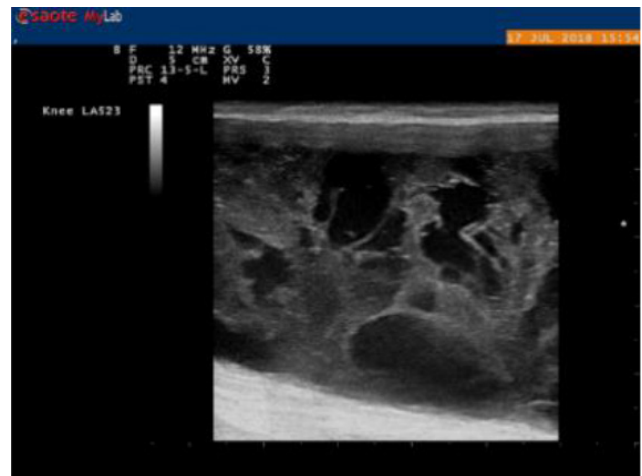


Figure 3: Ultrasound of the knee and synovial proliferation.

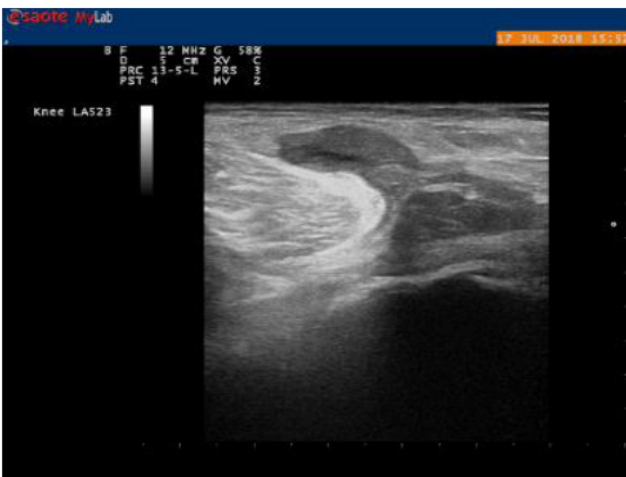


Figure 2: Ultrasound of the knee.

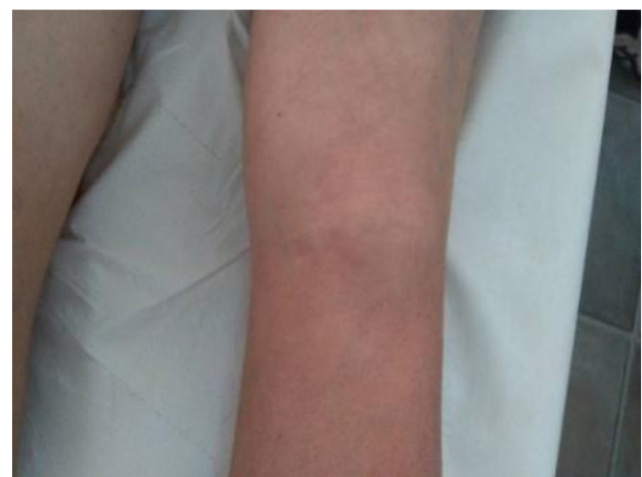

Figure 4: Regression of Bakers cyst.

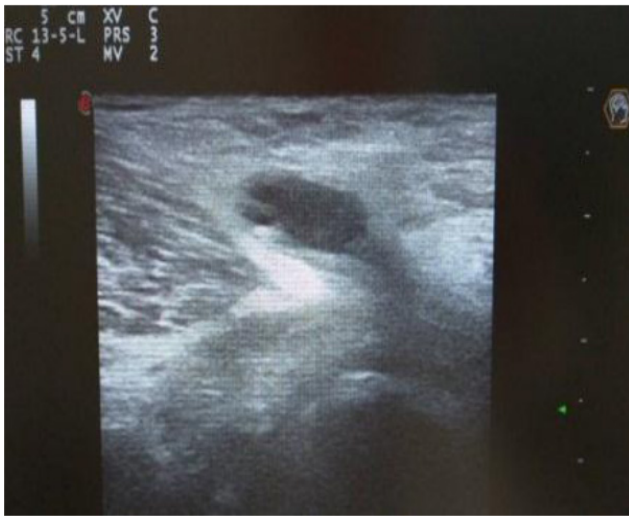

Figure 5: Regression of cyst – ultrasound.

week in May 2018 due to the new diagnosed leukopenia.

In physical examination tenderness of shoulder joints and right wrist was noted. Also, tumefaction in the area of the right elbow was registered (Figure 6).

In lab analyses there was no significant deviation: SED 12; CRP 0; RF 0; Anti CCP 6.8; Leu 4.14. Radiography of hands, knee, right elbow and feet showed changes that correspond to anatomical stage II of RA without progression in relation to the findings from 2017. Densitometry showed changes that corresponded with osteoporosis (Lumbar spine: BMD 0.747 g/cm², *t* score -2.7; Hip: BMD at 0.611 g/cm², *t* score -2.1). We introduced bisphosphonate into therapy. The ultrasound examination of the right lateral aspect of the elbow verified synovial cysts filled largely with synovial proliferators (Figure 7).

Due to moderate disease activity (DAS 28 3.9) during hospital treatment dosage of MTX was increased to 10mg a week. Also, it was suggested that antimalarial drug should be introduced in therapy after the ophthalmological examination as further increase in dose of MTX was limited due to leukopenia.

DISCUSSION

Synovial cysts therapy requires not just reduction of synovial effusion but the treatment of the primary disease that led to synovial overproduction. Modalities that are used for treating synovial cyst are varied and include physical procedures, corticosteroids and analgesics, aspiration and surgical procedures. Treatment of primary disease in a meniscus rupture includes partial meniscectomy while the systemic inflammatory disease

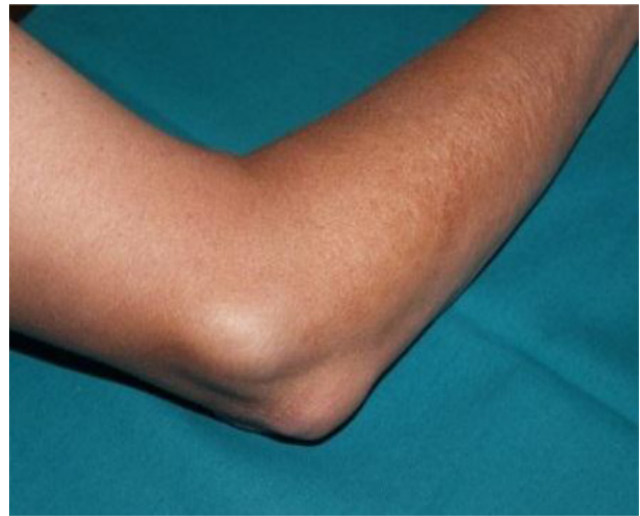

Figure 6: Tumefaction on right elbow.

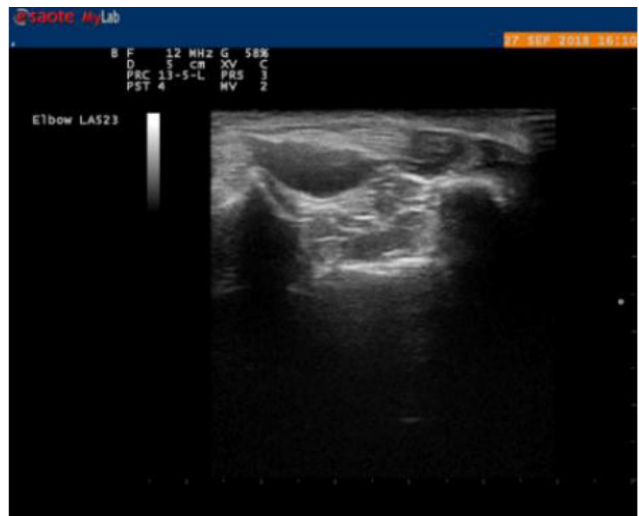

Figure 7: Ultrasound of right elbow.

of the synovial joints requires introduction of a Disease Modifying Drug (DMD).

In the first patient we had a regression of synovial cysts in a very short period of time. This was probably a result of high doses of corticosteroids since the DMDs effect occurs after 6 to 8 weeks after initiation of therapy.¹⁴

Synovial cyst in the other patient is a true rarity. In fact, so far there is no single published article about synovial cyst on elbow. Localization, consistency and ultrasound findings suggest that it is not bursitis but a real synovial cyst. The elbow bursitis is usually localized over the olecranon while in our patient the tumefaction was located laterally. Also, the ultrasound showed communication between the elbow joint and tumefaction which suggests that it was a synovial cyst. Elbow cyst persists two years so it is unlikely that the introduction of corticosteroids would have the same effect as in the

first patient. On the other hand, the tumefaction is small in size and does not affect patient's daily activities. That is way more aggressive treatment method such as needle aspiration or cystectomy is not necessary.

CONCLUSION

Bakers cyst is a synovial effusion which can be found in many systemic inflammatory diseases. It is not-so-rare disorder with usually good response to treatment. On the other hand, synovial cyst on elbow is a rare finding which is resistant to common therapy.

ACKNOWLEDGEMENT

Authors would like to thank Institute for Treatment and Rehabilitation Niška Banja, Niš, Serbia for all the support.

CONFLICT OF INTEREST

Author declare no conflict of interest.

ABBREVIATIONS

RA: Rheumatoid Arthritis; **MTX:** Methotrexate; **DMD:** Disease modifying drug; **BMD:** Bone mineral density.

SUMMARY

Patient with newly diagnosed rheumatoid arthritis developed huge Bakers cyst on the right knee. Application of corticosteroids caused the withdrawal of synovial effusion. On the other hand, in patient with synovial cyst on the elbow nor corticosteroids nor disease modifying drug did not result in regression of effusion.

REFERENCES

1. Morant B. On the formation of synovial cysts in the leg in connection with disease of the knee-joint. *Clinical Orthopaedics and Related Research*. 1994;299:2-10.
2. Andonopoulos AP, Yarmenitis S, Sfountouris H, Siampilis D, Zervas C, Bounas A. Baker's cyst in rheumatoid arthritis: An ultrasonographic study with a high-resolution technique. *Clinical and Experimental Rheumatology*. 1995;13(5):633-6.
3. Keng-Yi WU, Deng-Ho Y, Chun-Wen C. Pyogenic Baker cyst in a patient with psoriatic arthritis during etanercept therapy. *Annals of Saudi Medicine*. 2015;35(3):260.
4. William D, Kambiz M, Ami BA. Floating Tophi in a Baker Cyst Secondary to Gout: Ultrasound Features and Differential Diagnosis. *Ultrasound Quarterly*. 2015;31(3):189-91.
5. Artul S, Jabaly-Habib H, Artoul F, Habib G. The association between Baker's cyst and medial meniscal tear in patients with symptomatic knee using ultrasonography. *Clinical Imaging*. 2015;39(4):659-61.
6. Billiers J, Lascombes P, Peter R. Popliteal cysts: Etiologic and therapeutic approach. *Rev Med Suisse*. 2014;10(432):1211-5.
7. Frush TJ, Noyes FR. Baker's cyst: Diagnostic and surgical considerations. *Sports Health*. 2015;7(4):359-65.
8. Ward EE, Jacobson JA, Fessell DP, Hayes CW, Holsbeeck MV. Sonographic detection of Baker's cysts: Comparison with MR imaging. *American Journal of Roentgenology*. 2001;176(2):373-80.
9. Langsfeld M, Matteson B, Johnson W, Wascher D, Goodnough J, Weinstein E. Baker's cysts mimicking the symptoms of deep vein thrombosis: Diagnosis with venous duplex scanning. *Journal of Vascular Surgery*. 1997;25(4):658-62.
10. McDonald DG, Leopold GR. Ultrasound B-scanning in the differentiation of Baker's cyst and thrombophlebitis. *The British Journal of Radiology*. 1972;45(538):729-32.
11. Fritschy D, Fasel J, Imbert JC, Bianchi S, Verdonk R, Wirth CJ. The popliteal cyst. *Knee Surgery, Sports Traumatology, Arthroscopy*. 2006;14(7):623-8.
12. DiSante L, Paoloni M, Ioppolo F, Dimaggio M, DiRenzo S, Santilli V. Ultrasound-guided aspiration and corticosteroid injection of Baker's cysts in knee osteoarthritis: A prospective observational study. *American Journal of Physical Medicine and Rehabilitation*. 2010;89(12):970-5.
13. Sansone V, DePonti A. Arthroscopic treatment of popliteal cyst and associated intra-articular knee disorders in adults. *Arthroscopy: The Journal of Arthroscopic and Related Surgery*. 1999;15(4):368-72.
14. Smolen JS, Landewé R, Breedveld FC, Buch M, Burmester G, Dougados M, *et al.* EULAR recommendations for the management of rheumatoid arthritis with synthetic and biological disease-modifying antirheumatic drugs: 2013 update. *Annals of the Rheumatic Diseases*. 2014;73(3):492-509.