

Uterine Fibroids: A Review

Nivethithai P*, Nikhat SR, Rajesh BV

Faculty of Pharmacy, MESCO College of Pharmacy, Hyderabad.

Address for Correspondence: nivempharm@yahoo.co.in

Abstract

Uterine fibroids or Leiomyomas are benign tumors of uterus. Genetic abnormalities, alteration in growth factor (proteins formed in the body that direct the rate and extent of cell proliferation) expression, abnormalities in the vascular (blood vessel) system, and tissue response to injury have all been suggested to play a role in the development of uterine fibroids. Every year thousands of women hear the frightening diagnosis of fibroids in the uterus. In most of the women, uterine fibroids are caused when exposed to high levels of toxins, these toxins are artificial chemicals that are structurally similar to the Estrogen, naturally found in the human body. The present review focuses on the pathology, diagnosis, histology, medication options and surgical treatment of fibroids.

Key words: Estrogen, fibroids, tumors

INTRODUCTION

Uterine fibroid also referred to as uterine leiomyomata, uterine leiomyomas or uterine myomas are benign growth of womb (uterine) muscle, they are composed of smooth muscle layer accompanying connective tissues of the uterus¹. Most leiomyomas occur in the fundus and body of the uterus; only 3% occur in the cervix. They are most common towards the end of the reproductive years. They exist sometimes singly but most often are multiple, or diffuse and if the uterus contain too many leiomyomas to count, it is referred to as uterine leiomyomatosis². They are more common in obese women and probably some genetic determinant and they are less common in smokers. Majority of fibroids grow as a women gets older, and tend to shrink after menopause.³

ETIOLOGY AND PREVALENCE

The exact reason underlying in uterine fibroid remains unknown. National Institute of Child Health and human development (NICHD), part of the national institute of Health (NIH) within the US Department of health and Human service (DHHS), is trying to learn more about uterine fibroid, through research into their causes and treatments. As research works are done, NICHD scientists are exploring genetics, hormones, the immune system and environmental factors that may play a role in starting the growth of fibroids and or in continuing the growths. This information could lead to a cure for uterine fibroids that does not involve taking out of uterus. Someday, health care providers may even be able to prevent uterine fibroids from getting at all.⁴

Family history is a key factor, since there is often a history of fibroid developing in women of the same family. About 20 – 40 % of women will be diagnosed with leiomyoma.⁵ This condition is common in black women (3:1) than they do in white women (9:1)². Estrogen receptors on fibroid cause them to respond to estrogen stimulation during the reproductive years. During hypoestrogenic states such as after menopause, leiomyoma are expected to shrink. Leiomyoma are more common in overweight women because of increased estrogen from adipose aromatase activity.⁶ Researchers think that more than one factor could play a role.⁷ These factors could be:

- ✎ Hormonal (affected by estrogen and progesterone levels)
- ✎ Genetic (runs in families)

PATHOLOGY AND HISTOLOGY

Leiomyomas arise from the overgrowth of smooth muscle and connective tissue in the uterus. Histologically, a monoclonal proliferation of smooth muscle cells occurs. Estrogen and Progesterone receptors are present on fibroids. Elevated estrogen levels may cause fibroid enlargement. Infertility may occur as a result of narrowing of the isthmus portion of the fallopian tube or as a consequence of interference with implantation, especially interference caused by submucosal fibroids. Rarely, uterine leiomyoma may undergo malignant degeneration to become a sarcoma.²

Theories of fibroid formation

Until recently, the steroid hormones estrogen and progesterone were considered the most important

regulators of leiomyoma growth. There is abundant evidence that estrogen promotes fibroid growth including the clinical observations that fibroids grow in the presence of high levels of estrogen, such as during the reproductive years, and that they regress in the presence of low levels of estrogen, such as following menopause or during gonadotropin releasing hormone (GnRH) agonist therapy. Furthermore, fibroids have higher estrogen concentrations, bind more estrogen, have more estrogen receptors, and convert estradiol (a more active form of estrogen) to estrone (a less active form of estrogen) more slowly than normal myometrium.

Progesterone is also thought to play a role in fibroid growth. More specifically, clinical studies suggest progesterone facilitates the growth of fibroids. For example, fibroid size increases during treatment with synthetic progestones. Combination GnRH agonist and progesterone therapy has been shown to have no effect on uterine volume, in contrast to GnRH agonist therapy alone which has been shown to reduce uterine volume. The observation that fibroids regress with the antiprogestone agent, RU-486, further supports the role of progesterone as a promoter of fibroid growth. Histologically, fibroids from patients treated with progesterone show more cellular growth than those from patients without progesterone therapy. Biochemically, fibroids have higher progesterone receptor concentrations than normal myometrium. Together, these data suggest that progesterone also enhances fibroid growth.

Other hormones such as growth hormone (GH) and prolactin (PRL) are also thought to promote fibroid growth, but their role is even less well defined.

More recently, growth factors, which are small proteins that affect cell growth, have been shown to mediate the growth-promoting effects of estrogen and to play an important role in the development of fibroid tumors. Potentially important factors in fibroid growth include transforming growth factor-beta, basic fibroblast growth factor, epidermal growth factor, insulin-like growth factor, and platelet-derived growth factor.

Overall, estrogen, progesterone, and growth factors likely promote tumor growth, but only after the initiation of tumor formation. This initiating event remains unknown, although recent evidence suggests there is a strong inherited component to fibroid development. Indirect evidence for this hypothesis is as follows. First, fibroids are at least twice as common in black women than in white women. Although racial differences in

socioeconomic status and access to health care, as well as racial differences in known risk factors for fibroids, may contribute to this finding, two recent studies suggest that these factors do not completely explain the discrepancy. Secondly, another study found a genetic predisposition for hysterectomy as indicated by a two fold higher twin pair correlation for hysterectomy in identical versus fraternal twins. Thirdly, there exists a rare heritable form of uterine fibroids in association with fibroids of the skin called Reed's syndrome. Finally, a recent Russian studies suggest that women with a family history of fibroids are twice as likely to develop fibroids than women with no family history. Unfortunately, few scientific studies directly examine the genetic component of fibroid development.

Recently, researchers at the Center for Uterine Fibroids have identified mutations in two genes, HMGI(C) and HMGI(Y), that appear to be important in the development of some fibroids. Normally, these genes code for proteins that help control cell growth by indirectly regulating DNA transcription. However, mutations in these genes are probably secondary changes in already genetically susceptible cells. Therefore, it is likely that other gene(s) crucial for fibroid development exist that have not yet been identified.⁸

Leiomyomas grossly appear as round, well circumscribed (but not encapsulated), solid nodules that are white or tan and show whorled appearance on histological section [Figure 1]. Microscopically, tumor cells resemble normal cells (elongated, spindle-shaped, with a cigar shaped nucleus) and form bundles with different (whorled). These cells are uniform in size and shape, with scarce mitosis.^{9,10}

TYPES OF UTERINE FIBROIDS

Growth and location are the main factors that determine if a fibroid leads to symptoms and problems.⁵ A small lesion can be symptomatic if located within the uterine cavity while a large lesion on the outside of the uterus may go unnoticed. Different locations [Figure 2] are classified as follows:

- Intramural fibroids are located within the wall of the uterus and are the most common type; unless they may be asymptomatic.
- Subserosal fibroids are located underneath the mucosal (peritoneal) surface of the uterus and can become very large. They can also grow out in papillary manner to become pedunculated fibroids. These pedunculated growths can actually detach from the uterus to become a parasitic leiomyoma.

Fig.1: Micrograph of a leiomyoma

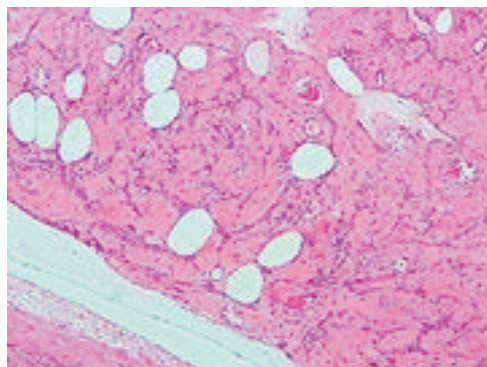
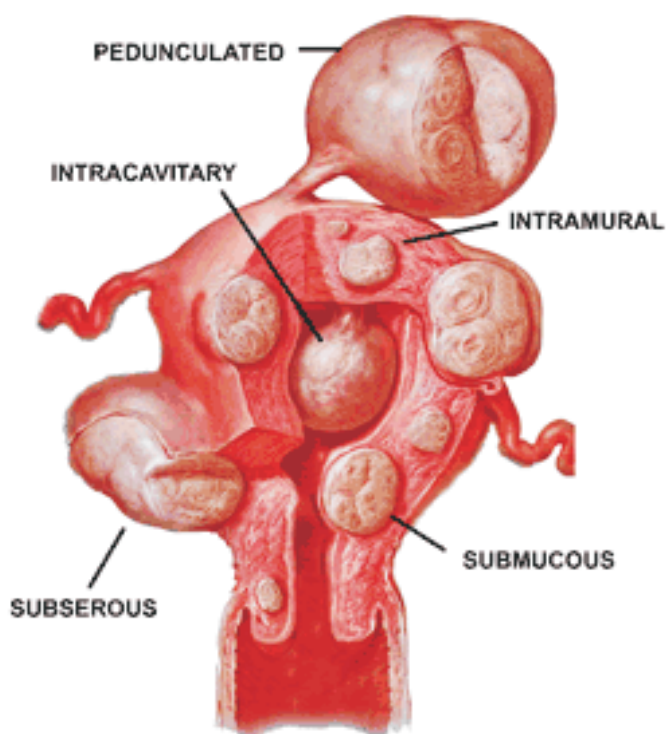


Fig.2: Types of Fibroids



- Submucosal fibroids are located in the muscle beneath the endometrium of the uterus and distort the uterine cavity; even small lesion in this location may lead to bleeding and infertility. A pedunculated lesion within the cavity is termed as intracavitary fibroid and can be passed through the cervix.
- Cervical fibroids are located in the wall of the cervix (neck of the uterus). Rarely fibroids are found in the supporting structures (round, ligament, broad ligament, or uterosacral ligament) of the uterus that also contain smooth muscle tissue.

Fibroids may be single or multiple. Most fibroids start in an intramural location that is the layer of the muscle of the uterus. With further growth, some lesions may develop towards the outside of the uterus or towards the internal cavity. Secondary changes that may develop within fibroids are hemorrhage, necrosis, calcification, and cystic changes.¹¹

SYMPTOMS OF UTERINE FIBROIDS

The most common symptoms of women with fibroids are pressure symptoms and heavy periods. An enlarged womb will place pressure on the bladder giving increased

symptoms.^{7]} Generally, symptoms include abnormal gynecologic hemorrhage, heavy or painful periods, abdominal discomfort or bloating, painful defecation, back ache, urinary frequency or retention and in some cases, infertility. There may be pain during intercourse, depending on the location of the fibroid. During pregnancy they may be miscarriage, bleeding, premature labor or interference with the position of the fetus.¹² While fibroids are common, they are not a typical cause for infertility, if a fibroid is located in a submucosal position and it is thought that this location may interfere with the function of the lining and the ability of the embryo to implant. Also larger fibroids may distort or block the fallopian tubes.¹³

DIAGNOSIS

The diagnosis is likely if bimanual pelvic examination detects an enlarged, mobile, irregular uterus that is palpable above the pelvic symphysis. Confirmation requires imaging. Gynecologic ultrasonography (ULTRASOUND) has evolved as the standard tool to evaluate the uterus for fibroids. Occasionally, when trying to determine if a fibroid is present in the uterine cavity (endometrial cavity), a hysterosalpingogram (HSG) is done. In this procedure, an ultrasound exam is done while contrast fluid is injected into the uterus from the cervix. The fluid is visualized in the endometrial cavity and thus outline any masses that are inside, such as submucosal fibroids. If ultrasonography is inconclusive, MRI, the most accurate imaging test, is done. Also magnetic resonance imaging (MRI) can be used to define the depiction of the size and location of the fibroids within the uterus.^{1,3,6}

FIBROID TREATMENT OPTIONS

Choice of treatment

Treatment should be individualized, but some factors can help with the decision:

- ☞ Asymptomatic fibroids: No treatment.
- ☞ Postmenopausal women: Trial of expectant management (because symptoms tend to remit as fibroids regress)
- ☞ Surgically accessible symptomatic fibroids, particularly if conception may be desired: Myomectomy
- ☞ Symptomatic fibroids that are not clearly surgically accessible: Uterine artery embolization or another new technique (eg, high-intensity focused sonography)
- ☞ Intolerable symptoms when other treatments were ineffective, particularly if conception is not desired: Hysterectomy, possibly preceded by drug therapy (eg,

with GnRH analogues)¹⁴

Obviously fibroids that are causing significant symptoms need treatment.

Non-surgical Treatment

Non-surgical techniques are usually hormonal in nature and include the use of drugs

- ☞ Gonadotropin-releasing hormone analogs (GnRH analogs) are the drugs that turn off the production of estrogen from the ovaries which are given for three to six months, if successful, they can shrink fibroid upto 50% and may cause osteoporosis.¹
- ☞ Aromatase inhibitors and Progesterone have been used experimentally to reduce the size of fibroids.
- ☞ Mifepristone is an antiprogestin drug which reduce the bleeding associated with fibroids, but associated with side effects such as overgrowth (hyperplasia) of the endometrium (uterine lining)¹. It was effective in a placebo-controlled pilot study.¹⁵
- ☞ Danazol (Danocrine) is an androgenic steroid hormone that has been used to reduce bleeding in women with fibroids, since the drug cause menstruation to cease. However, danazol does not appear to shrink the size of fibroids.
- ☞ Raloxifene (Evista) used to prevent and treat osteoporosis and reduce the size of fibroids in postmenopausal women.¹
- ☞ Low dose formulations of oral contraceptives pills, either combination pills with estrogen or progestin-only are prescribed to reduce uterine bleeding and cramps associated with fibroids.¹³
- ☞ Drugs which lower oestrogen levels may be used to shrink or temporarily halt fibroid growth, particularly before surgery. However, since the drugs often cause menopause-like symptoms such as hot flushes, vaginal dryness and decrease bone density. A course of treatment usually lasts only three to six months. Fibroids often continue growing once hormone therapy stops.¹⁶
- ☞ HIFU (High intensity focused ultrasound), also called Magnetic Resonance guided Focused Ultrasound (MRgFUS), is a non-invasive intervention that uses high intensity focused ultrasound waves to ablate (destroy) tissue in combination with Magnetic Resonance Imaging (MRI), which guides and monitors the treatment. This technique is relatively new; it was approved by the FDA in 2004.¹⁷ This cutting-edge technology, which offers women the option of same-day, non-surgical treatment. With increasing availability of conservative treatment choices, both patients and their physicians have the opportunity to

individualize therapy based on the goals of each patient¹⁸

✍ **Surgical Treatment**

Surgical removal of a uterine fibroid usually takes place via hysterectomy, in which entire uterus is removed, or myomectomy, in which only the fibroid is removed. It is possible to remove multiple fibroids during a myomectomy. Although a myomectomy cannot prevent the recurrence of fibroids at a later date, such surgery is increasingly recommended, especially in the case of women who have not completed bearing children or who express an explicit desire to retain the uterus. Myomectomy can be done through three different ways:

- Hysteroscopic myomectomy – Fibroid removed by the use of a resectoscope, an endoscopic instrument with a built in loop that can use high frequency electrical energy to cut tissue with either local or general anesthesia used. It is not recommended for submucosal fibroids. A French study collected results from 235 patients suffering from submucous myomas who were treated with hysteroscopic myomectomies; in none of these cases was the fibroid greater than 5 cm.¹⁹

- Laparoscopic myomectomy - It requires standard open incision into the uterus with the help of laparoscope to remove the fibroids. It is easier to remove when they are on a stalk or close to the surface. The advantage is that it lowers morbidity rates and faster recovery than laparotomic myomectomy.²⁰

- Laparotomic myomectomy – Also known as open or abdominal myomectomy is the most invasive surgical procedure to remove fibroids. Here the incision is made in the abdominal wall to remove fibroid from uterus. A particularly extensive laparotomic procedure may necessitate that any future births be conducted by Caesarean section.¹³

- Endometrial Ablation – The lining of the uterus is removed or destroyed to control heavy bleeding. This can be done with laser, wire loops, boiling water, electric current, freezing and other methods. About three in ten women have much lighter bleeding. But, a women cannot have children after this surgery.

- Myolysis – Needle is inserted into the fibroids usually guided by laproscopy, and electric current or freezing is used to destroy the fibroids.⁷

- Uterine artery embolization (UAE) – Using intervention radiology techniques, small beads of a compound called polyvinyl alcohol, which are

injected through a catheter into the arteries that feed the fibroid, these beads obstruct the blood supply to the fibroid and starve it of blood and oxygen¹. UAE results in the supposed shrinking of the fibroid and the uterus, thus alleviating the symptoms. However, it is important to note that significant adverse effects resulting from uterine artery embolization have been reported and documente in the medical literature including death, infection, misembolization, loss of ovarian function, unsuccessful fibroid expulsion, pain, foul vaginal odor, hysterectomy, and failure of embolization surgery^{5,6}

- Uterine artery occlusion (UAO) – It involves clamping the involved uterine arteries as opposed to injecting the polyvinyl alcohol beads, is currently under investigation as a potential alternative to UAE.¹

CONCLUSION

Despite the major public health impact of leiomyomas, little is known about their cause. Researchers are studying families with at least one pair of siblings affected by fibroids to search for gene(s) that predispose women to fibroid development. Ultimately, understanding the hormones, growth factors, and gene(s) involved in the formation and growth of fibroid tumors may lead to innovative, less invasive treatment options. Management depends on the symptoms, location and size of the fibroids, and the patient's desire to conceive.

REFERENCES

1. http://www.medicinet.com/uterine_fibroids/discussion-269.htm
2. Philip Thomason. Leiomyoma, Uterus (Fibroid) [online]. 2008 May 6. Available from: URL: <http://emedicine.medscape.com/article/405676-overview>.
3. Goto A, Takeuci s, Sugimura K, Maruo T. “usefulness of Gd-DTPA contrast-enhanced dynamic MRI and serum determination of LDH and its isozymes in the differential diagnosis of leiomyosarcoma from degenerated leiomyoma of the uterus”. *Int. j. gynecol. Cancer* 12 (4): 354-61.
4. <http://www.nichd.nih.gov/publications/puds/fibroids.cfm>
5. Wallach EE, Vlahos NF. “Uterine myomas: an overview of development, clinical features, and management”. *Obstet Gynecol* 104 (2004), pp. 393-406.
6. Uterine Fibroids- The Merck Manuals Online Medical Library

7. http://www.womenshealth.gov/FAQ/uterine_fibroids.cfm
8. <http://www.fibroids.net>
9. Nisolle M, Gillerot S, Casanas-Roux F, Squifflet J, Berliere M, Donnez J (1999). Immunohisto-chemical study of the proliferation index, oestrogen receptor and progesterone receptors A and B in leiomyomata and normal myometrium during the menstrual cycle and under gonadotrophin-releasing hormone agonist therapy. *Hum Reprod* 14(11):2844-50.
10. Advances in Uterine Leiomyoma Research: The Progesterone Hypothesis. <http://ehp.niehs.nih.gov/members/2000/suppl-5/791-793rein/rein-full.html>. Retrieved 2007-08-25.
11. http://en.wikipedia.org/wiki/uterine_fibroids
12. <http://www.fibroidtumors.net>
13. American Society of Reproductive Medicine Patient Booklet: Uterine Fibroids, 2003.
14. The Merck Manuals Online Medical Library - Fibroids in uterus. February 07th 2009/category: Fibroids
15. Engman M, Granberg S, Willians ARW, Meng CX, Lalitkumar PGL, Gemzell-Danielsson k (August 2009). "Mifepristone for treatment of Uterine Leiomyoma. A Prospective Randomized Placebo Controlled Trial", *Human Reproduction* 24 (8): 1870-9.
16. <http://www.babycenter.in/preconception/susceptingaproblem/fibroid>
17. FDA (2004-10-22). FDA Approves New Device to treat Uterine Fibroids. <http://www.fda.gov/bbs/topics/answers/2004/ans01319.html>. Retrieved 2008-05-26
18. <http://www.dukehealth.org>
19. Polena, V., et al. "Long-term results of hysteroscopic myomectomy in 235 patients." *European journal of Obstetrics and Gynecology and Reproductive Biology*. 130(2007): 232-237.
20. Agdi M, and Tulandi T. "Endoscopic management of uterine fibroids." *Best Practice and Research Clinical Obstetrics and Gynecology*, online publication 4th Mar 2008.